

Review

Charcot's foot: Newest findings on its pathophysiology, diagnosis and treatment

L. Molines*, P. Darmon, D. Raccach

Department of Nutrition, Metabolic Diseases and Endocrinology, Sainte-Marguerite Hospital, 270, boulevard de Sainte-Marguerite, 13274 Marseille cedex 9, France

Received 16 April 2010; accepted 19 April 2010
Available online 8 June 2010

Abstract

Charcot neuro-osteoarthropathy (CNO) is one of the more devastating complications affecting diabetic patients with peripheral and/or autonomic neuropathy. The acute phase of the disease is often misdiagnosed, and can rapidly lead to deformity and amputation. The rapid progression towards foot deformation calls for early detection and intervention. Classical neurotraumatic and neurotrophic theories fail to explain all of the features of the condition, although recent advances that have clarified the mechanisms underlying the pathophysiology may make up for this lack. In particular, new data have emerged on the central role of the RANK/RANK-ligand (RANK-L)/osteoprotegerin (OPG) system in the pathogenesis of osteopenia. Also, it is now recognized that the acute phase of CNO can be triggered by any factor leading to local inflammation of the foot, especially in predisposed patients. As the cornerstone of treatment remains any method that avoids weight-bearing on the foot, the primary importance of the RANK/RANK-L/OPG signalling pathway is that it opens up the field to new treatment strategies for the future.

© 2010 Elsevier Masson SAS. All rights reserved.

Keywords: Charcot neuro-osteoarthropathy; Diabetic foot; Diabetic neuropathy; RANK-L; Osteoprotegerin; Review

Résumé

Le pied de Charcot : actualités physiopathologiques, diagnostiques et thérapeutiques.

L'ostéoarthropathie de Charcot est une complication grave qui touche exclusivement les patients diabétiques présentant une neuropathie périphérique et/ou autonome. La phase aiguë est rarement identifiée comme telle. Or, seul un diagnostic précoce suivi d'une intervention rapide peuvent limiter l'évolution vers des déformations du pied, voire l'amputation. Si les théories classiquement reconnues, neurotraumatique et neurotrophique, sont insuffisantes pour expliquer tous les aspects de l'affection, la compréhension récente des mécanismes impliqués dans la pathogénie de la maladie, et notamment l'implication du système RANK/RANK-L/OPG, ont permis de pallier à ces manquements. Il est désormais clair que tout événement qui conduit à une réaction inflammatoire locale, et plus seulement un traumatisme mineur, peut déclencher cette phase aiguë chez un individu prédisposé. La pierre angulaire de la prise en charge reste la mise en décharge, mais la place centrale tenue par la voie de signalisation RANK/RANK-L/OPG dans la pathogénie de l'affection laisse envisager de nouvelles stratégies thérapeutiques ciblées dans l'avenir.

© 2010 Elsevier Masson SAS. Tous droits réservés.

Mots clés : Ostéoarthropathie de Charcot ; Pied diabétique ; Neuropathie diabétique ; RANK-L ; Ostéoprotégérine ; Revue

1. Introduction

Charcot neuro-osteoarthropathy (CNO) is a disabling complication that affects diabetic patients who have mild-to-severe

neuropathy. It can lead to disruption of the bony architecture of the foot, foot deformity, recurrent foot ulceration and, ultimately, amputation.

John Kearsley Mitchell was the first physician, in 1831, to clearly describe the destruction of bones and joints leading to denervation of the lower limb secondary to a spinal cord lesion first in 12 cases, followed by 35 others two years later [1,2]. However, it was Jean-Martin Charcot, a French neurologist, who

* Corresponding author. Tel.: +33 4 91 74 55 00; fax: +33 4 91 74 55 03.
E-mail address: laurent.molines@ap-hm.fr (L. Molines).

provided the precise histopathological description of the neuropathological disorder as a complication of the tabes dorsalis in 1868 [3]. In 1881, Charcot received international acclaim for his research on tabetic arthropathies during the seventh International Medical Congress held in London. What he described at this congress was clearly a neuropathological osteoarthropathy affecting both the long bones and their joints, which was then acknowledged as a distinct pathological entity and dubbed ‘Charcot’s disease’ [4]. It was not until 1936 that William Reilly Jordan described Charcot’s disease as a complication of diabetic neuropathy [5], and diabetes is now recognized to be the most common cause of the condition worldwide. However, CNO has also been associated with other conditions, including neurological disorders such as spina bifida, cerebral palsy, meningomyelocoele and syringomyelia [6,7], infections such as leprosy [8], and toxic syndromes such as alcohol abuse [9].

2. Clinical presentation

The incidence and prevalence of CNO are difficult to determine mainly because of the lack of clear clinical and radiological diagnostic criteria, which has led to many misdiagnosed and missed cases. However, the reported prevalence has ranged from 0.1 to 0.4% [10].

From a clinical point of view, acute CNO can occur spontaneously or be triggered by minor trauma, and typically presents with acute or subacute inflammation of the foot, which suddenly becomes swollen, red, warmer than the contralateral side and sometimes painful, despite the sensitive neuropathy of the diabetic patient. Pedal pulses are typically easy to feel because of the underlying neuropathy. There is neither fever nor any major biological inflammatory syndrome, and this clinical presentation has often led to inaccurate diagnoses such as microcrystalline arthropathy (gout or chondrocalcinosis), neuroalgodystrophy and cellulitis. However, the acute phase of CNO often goes unnoticed, resulting in a delayed positive diagnosis and progression to the chronic phase, with irreversible deformation.

The main problem is that, at this stage of the disease, not only is the clinical diagnosis not easy to make, but standard radiography often cannot distinguish acute CNO from other conditions. Indeed, X-ray radiography may fail to document any evidence of fracture and/or dislocation. Radioisotope technetium (Tc-99m) bone scintigraphy has good sensitivity, but poor specificity, for osseous pathology and only shows increased focal uptake during the bony phase. Only magnetic resonance imaging (MRI) is capable of revealing, in greater detail, the nature of the bony damage and evidence of inflammation in the bone (subchondral bone-marrow oedema with or without microfracture) as well as in the adjacent soft tissues [11,12]. MRI is particularly useful in the earliest stages of the disease, as there is a significant correlation between the intensity of bone-marrow oedema and clinical parameters such as soft-tissue oedema or pain [13].

Different systems have been proposed to classify CNO, and the one most commonly used is an anatomically based system—the Sanders–Frykberg anatomical classification—that divides the foot into five zones, according to the joints involved [14]: type I involves the metatarsophalangeal and interpha-

langeal joints; type II involves the tarsometatarsal joints; type III involves the tarsal joints; type IV involves the subtalar joints; and type V involves the calcaneum. This classification has proved especially helpful in predicting prevalence and prognosis. Types I and II are the most common types, while types II and III are particularly associated with the risk of abnormal friction and ulceration, and types IV and V carry poor prognoses due to the effects of weight distribution during walking [15].

3. Pathogenesis

Pathogenetic knowledge has focused on purely mechanical theories for some time. Two theories, initially thought to be competing concepts, are now considered to be overlapping to varying degrees. On the one hand, the neurotraumatic theory proposes that, in the presence of sensorimotor neuropathy, abnormal plantar pressure occurs. This is supported by the amyotrophy of intrinsic muscles, and the imbalance between the extensor and flexor muscles. In addition, the bones and joints lose their protective sensory capacity, allowing repetitive trauma that, in turn, leads to excessive extension of the ligaments, and microfractures and more joint dislocation. On the other hand, the neurovascular theory suggests that the autonomic neuropathy leads to a hyperaemic state, with an increase in blood flow to the lower limbs due to the development of arteriovenous shunts [16]. The hyperaemia appears to cause osteopenia, bone resorption and bone weakening. Ultimately, it is on this weakened foot that, either spontaneously or due to minor trauma, microfractures and dislocations occur.

Although both these theories are attractive, they are not able to explain some of the typical features of acute CNO and, in particular, why the condition is unilateral while neuropathy is most often bilateral, why CNO is so infrequent while neuropathy is a common complication of diabetes, and what is the link with the inflammatory reaction that is initially observed.

However, a currently recognized novel theory is able to answer all of these questions. It is a more ‘inflammatory’ than ‘mechanical’ theory that also includes the idea of a triggering factor, most often a minor trauma that goes unnoticed because of the sensory neuropathy, but also sometimes a previous ulcer infection or foot surgery. The common link between these factors is local inflammation [17], and these factors are also all associated with the release of proinflammatory cytokines such as interleukin (IL)-1 β and tumour necrosis factor (TNF)- α , which are known mediators of bone resorption *via* excess osteoclastic activity [18]. Interestingly, however, a dissociation between the local inflammatory response related to the increased proinflammatory cytokine secretion and lack of systemic inflammatory response has been found in patients with acute CNO [19]. In such patients, these cytokines lead to an increased expression of the receptor activator of nuclear factor- κ B (RANK) ligand. The RANK ligand (RANK-L) is located in the cell membranes of osteoblasts and bone-marrow stromal cells, and belongs to the TNF superfamily. Its receptor (RANK) is expressed in the membrane of preosteoclasts and other cells of this membrane lineage, and belongs to the TNF-receptor superfamily. The involvement of the RANK/RANK-L signalling pathway in the pathogenesis

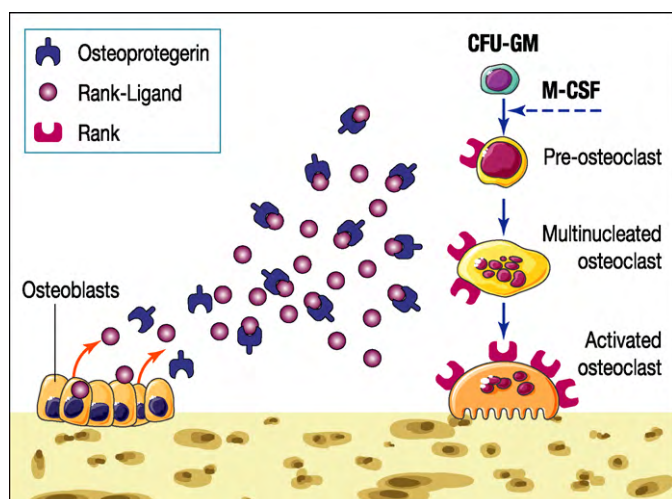


Fig. 1. Diagrammatic representation of the RANK/RANK-L/OPG signalling pathway in the process of bone resorption. On the one hand, RANK-L (receptor activator of nuclear factor- κ B ligand), a surface-bound molecule found on osteoblasts and bone-marrow stromal cells, binds to its specific membrane-bound receptor RANK (receptor activator of nuclear factor- κ B) at the surface of preosteoclasts and other cells of this lineage. The binding subsequently triggers a kinase cascade that promotes osteoclast differentiation, activation and survival. On the other hand, OPG (osteoprotegerin), which is also expressed by osteoblasts, acts as a decoy receptor to bind and effectively neutralize RANK-L which, in turn, limits excess osteoclastogenesis and osteolysis. CFU-GM: colony-forming unit granulocyte-macrophage; M-CSF: monocyte colony-stimulating factor.

of acute CNO was first hypothesized by Jeffcoate in 2004, who observed RANK-L overexpression in a variety of degenerative bone diseases, including rheumatoid arthritis, psoriatic arthritis, postmenopausal or glucocorticoid-induced osteoporosis and multiple myeloma [20,21]. RANK-L stimulates the expression of nuclear factor (NF)- κ B, a transcription factor that, in turn, induces the maturation of precursor cells into mature osteoclasts. At the same time, NF- κ B induces the increased expression of the glycoprotein osteoprotegerin (OPG), which acts as a decoy receptor for RANK-L to effectively neutralize its effect and so avoid excess osteolysis (Fig. 1). Different regulatory mechanisms of the RANK/RANK-L/OPG system are involved in bone remodelling, including other cytokines, growth factors and hormones that variably increase (TNF- α , glucocorticoids, parathyroid hormone) or suppress (sex steroids, calcitonin, calcitonin gene-related peptide, leptin) the expression of RANK-L and, thus, stimulate or inhibit bone turnover [22]. The role of this pathway in acute CNO pathogenesis is supported by the fact that the same RANK/RANK-L/OPG system is also involved in the process of medial arterial calcification, a feature that is strongly associated with both the distal symmetrical neuropathy of diabetes [23] and CNO [24,25]. Furthermore, although the involvement of RANK-L-mediated osteoclastic resorption in acute CNO is now clear [26], certain patients with diabetes and distal symmetrical neuropathy appear to be at greater risk of developing CNO, and this risk is at least partly due to genetic predisposition and, in particular, OPG polymorphisms [27].

A traumatic triggering factor causes the release of inflammatory cytokines that increase the expression of RANK-L, thereby

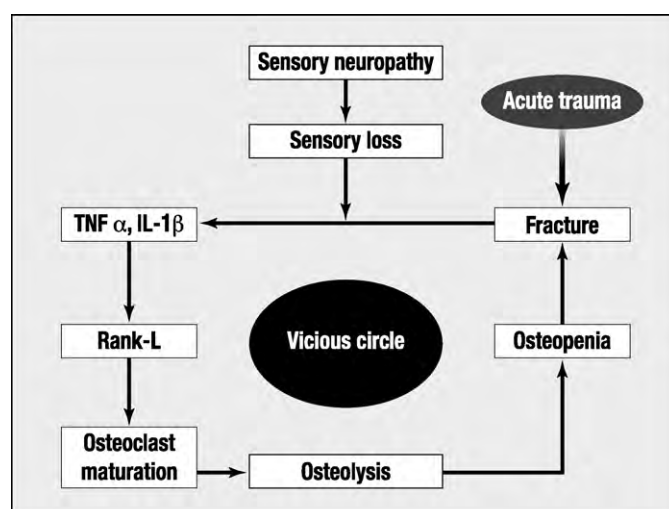


Fig. 2. Acute trauma leads to the release of proinflammatory cytokines, including tumour necrosis factor (TNF)- α and interleukin (IL)-1 β , which induces the increased expression of receptor activator of nuclear factor- κ B ligand (RANK-L), leading to osteoclast maturation, osteolysis and osteopenia. The process is normally limited by the offloading of weight in response to the pain caused by the local inflammation. However, in the presence of peripheral diabetic neuropathy, pain perception is altered, the foot is not immobilized, and trauma and inflammation continue to worsen, thus establishing a vicious circle of trauma, inflammation and progressive damage to the foot.

resulting in clinical signs of inflammation, osteoclast maturation and activation, and osteolysis. Physiologically, this process is limited by immobilization in response to the pain caused by local inflammation. However, when pain perception is reduced due to sensory neuropathy, there is no protective suppression, thereby allowing the inflammatory process to continue which, in turn, ultimately leads to osteolysis and bone breakdown. The result is the establishment of a vicious circle of inflammation and worsening structural damage to the foot (Fig. 2).

In practice, this indicates that it is essential that clinicians make the diagnosis of acute CNO early in the history of the condition to avoid its progression to the chronic, stable stage, with bony deformity and the classic ‘rocker-bottom’ appearance if the midfoot is involved. At this stage, the bony plantar prominence becomes a site of abnormally high pressure that particularly exposes the patient to the risk of chronic ulceration. It is at the acute phase before the appearance of the inflammatory foot that the clinician needs to resort to MRI to confirm the diagnosis.

4. Management

The aims of treatment in the acute phase of CNO are to stop the inflammatory process to break the vicious circle, to relieve pain, and to maintain the architecture of the foot and ankle to prevent deformity [28]. Because of a lack of randomized controlled studies comparing different ways of managing acute CNO, no regimen is currently proven to be more effective than others [29]. Indeed, the cornerstone of management remains immobilization to prevent the affected limb from bearing weight. At present, this is the only means of limiting the inflammatory pro-

cess that accompanies the beginning of the acute phase. Various non-weight-bearing devices are available, but do not necessarily lead to total immobilization. The most commonly used device is a plaster contact cast, which can bring about improvements in bone activity and skin temperature over 12 months of treatment [30]. On average, 18 months are required for the acute phase of CNO to subside [31], although the speed of healing differs according to its location on the foot. Acute CNO of the ankle, hindfoot or midfoot takes longer to heal than that of the forefoot [32]. A total contact cast appears to be safe in terms of ulceration, infection and hospitalization, and is also effective for healing plantar wounds associated with acute CNO [33]. However, the treatment may be difficult for the patient to accept and so requires an appropriate explanation. Other forms of foot immobilization have been successfully used in the acute phase of CNO, including the Charcot restraint orthotic walker, which allows the patient to apply their full weight and to walk [34], patellar tendon-bearing braces [35,36], and bivalved ankle-foot orthosis [37]. Prefabricated pneumatic walking braces, which are comfortable to use and may be removed at night, show similar plantar pressures compared with a total contact cast in healthy subjects, but they have yet to be evaluated in the treatment of acute CNO [38].

Anti-osteoclastic drugs are logical treatment options when bone turnover is excessive, and their efficacy has been studied in small randomized, double-blind, controlled trials. The bisphosphonate pamidronate was given as a single 90-mg infusion for 12 months to 39 diabetic patients with acute CNO in addition to the standard care of foot immobilization in one study [39]. This led to a significant fall in foot temperature, to improvement in the patients' symptom scores and to a reduction in bone turnover markers (urinary deoxypyridinoline and serum bone-specific alkaline phosphatase). More recently, the bisphosphonate alendronate was given as a 70-mg dose, once a week, to patients in a 6-month double-blind controlled trial [40], and resulted in significant clinical improvement, with a greater reduction in foot temperature and pain scores on visual analogue scales in the treated group. Also, serum collagen COOH-terminal telopeptide of type I collagen (ICTP) and hydroxyprolin, both markers of bone resorption, decreased significantly in the treated patients. Furthermore, a significant increase in bone mineral density, as assessed by dual-energy X-ray absorptiometry, was observed.

Calcitonin is another antiresorptive agent used to a lesser extent than bisphosphonates, mainly because of its mode of administration (subcutaneously or nasally). In a randomized controlled trial of 32 diabetic patients with acute CNO, intranasal salmon calcitonin was given at a dose of 200 IU/day with calcium supplementation and compared with calcium alone. In this study, foot skin temperature was reduced in both groups, with no significant between-group differences, although calcitonin treatment was associated with a significantly greater reduction in ICTP and bone-specific alkaline phosphatase [41].

Advances in our understanding of the mechanisms implicated in the pathogenesis of the acute phase of CNO—and, in particular, the central role played by activation of the RANK/RANK-L/OPG system—suggest new options for its treatment. Indeed, based on theoretical mechanisms, drugs such as specific TNF- α

antagonists (infliximab, etanercept, adalimumab) and RANK-L antagonists (denosumab) may be of particular interest and clinical relevance. In other bone disorders such as postmenopausal osteoporosis and rheumatoid arthritis, randomized controlled trials using denosumab showed promising results for bone mineral density and bone turnover [42,43].

5. Conclusion

Our knowledge and understanding of the pathogenesis of acute CNO has improved considerably over the past few years, such that we can now expect to find new types of specific treatment. However, the condition still often remains misdiagnosed, suggesting that clinicians need to be more vigilant, and that acute CNO should be considered in any diabetic patient with peripheral neuropathy presenting with a unilaterally erythematous, warm, swollen foot. Once suspected of having acute CNO, the affected foot should be promptly offloaded until the diagnosis is confirmed, preferably by early MRI. Indeed, the prognosis and progression to the chronic phase and foot deformities depends on early diagnosis and avoidance of weight-bearing.

Conflicts of interest

The authors do not have any conflicts of interest to declare.

References

- [1] Mitchell JK. On a new practice in acute and chronic rheumatism. *Am J Med Sci* 1831;8:55–64.
- [2] Mitchell JK. Further cases and observations relative to rheumatism. *Am J Med Sci* 1833;12:360.
- [3] Charcot JM. Sur quelques arthropathies qui paraissent dépendre d'une lésion du cerveau ou de la moelle épinière. *Arch Physiol Norm Pathol* 1868;1:161–78.
- [4] MacCormac W, Klockmann JW. Transactions of the international medical congress: seventh session held in London, August 2–9 1881 vol.1. Ballantyne, Hanson & Co: London 1881; p. 128–29.
- [5] Jordan WR. Neuritic manifestations in diabetes mellitus. *Arch Intern Med* 1936;57:307–66.
- [6] Nagarkatti DG, Banta JV, Thomson JD. Charcot arthropathy in spina bifida. *J Pediatr Orthop* 2000;20:82–7.
- [7] McKay DJ, Sheehan P, DeLauro TM, Iannuzzi LM. Vincristine-induced neuroarthropathy (Charcot's joint). *J Am Podiatr Med Assoc* 2000;90:478–80.
- [8] Horibe S, Tada K, Nagano J. Neuroarthropathy of the foot in leprosy. *J Bone Joint Surg Br* 1988;70:481–5.
- [9] Vera AI, Nixon BP. Charcot foot in an alcoholic patient. A case report. *J Am Podiatr Med Assoc* 1995;85:318–20.
- [10] Rajbhandari SM, Jenkins RC, Davies C, Tesfaye S. Charcot neuroarthropathy in diabetes mellitus. *Diabetologia* 2002;45:1085–96.
- [11] Edmonds ME, Petrove NL, Elias DA. The earliest magnetic resonance imaging sign of mid-foot charcot osteoarthropathy is oedema of subchondral (subarticular) bone marrow which needs prompt therapeutic offloading. *Diabet Med* 2005;22(Suppl. 2):93. P272.
- [12] Chantelau E, Poll LW. Evaluation of the diabetic foot by MR imaging or plain radiography—an observational study. *Exp Clin Endocrinol Diabetes* 2006;114:428–31.
- [13] Schlossbauer T, Mioc T, Sommerey S, Kessler SB, Reiser MF, Pfeifer KJ. Magnetic resonance imaging in early stage charcot arthropathy: correlation of imaging findings and clinical symptoms. *Eur J Med Res* 2008;22:409–14.

- [14] Sanders LJ, Frykberg RG. Diabetic neuropathic osteoarthropathy: the Charcot foot. In: Frykberg RG, editor. *The high risk foot in diabetes mellitus*. New York: Churchill Livingstone; 1991. p. 297–333.
- [15] Edmonds ME, Clarks MB, Newton S, Barrett J, Watkins PJ. Increased uptake of bone radiopharmaceutical in diabetic neuropathy. *Q J Med* 1985;57:843–55.
- [16] Jeffcoate WJ, Game FL, Cavanagh PR. The role of proinflammatory cytokines in the cause of neuropathic osteoarthropathy (acute Charcot foot) in diabetes. *Lancet* 2005;366:2058–61.
- [17] Baumhauer JF, O'Keefe RJ, Schon LC, Pinzur MS. Cytokine-induced osteoclastic bone resorption in Charcot arthropathy: an immunohistochemical study. *Foot Ankle Int* 2006;27:797–800.
- [18] Petrova NL, Moniz C, Elias DA, Buxton-Thomas M, Bates M, Edmonds ME. Is there a systemic inflammatory response in the acute Charcot foot? *Diabetes Care* 2007;30:997–8.
- [19] Jeffcoate WJ. Vascular calcification and osteolysis in diabetic neuropathy. Is RANK-L the missing link? *Diabetologia* 2004;47:1488–92.
- [20] Vega D, Maalouf NM, Sakhaee K. The role of receptor activator of nuclear factor- κ B (RANK)/RANK Ligand/Osteoprotegerin: clinical implications. *J Clin Endocrinol Metab* 2007;92:4514–21.
- [21] Jeffcoate WJ. Charcot neuro-osteoarthropathy. *Diabetes Metab Res Rev* 2008;24(Suppl. 1):S62–5.
- [22] Boyle WJ, Simonet WS, Lacey DL. Osteoclast differentiation and activation. *Nature* 2003;423:337–42.
- [23] Jeffcoate WJ, Rasmussen LM, Hofbauer LC, Game FL. Medial arterial calcification in diabetes and its relationship to neuropathy. *Diabetologia* 2009;52:2478–88.
- [24] Sinha S, Munichoodappa C, Kozak GP. Neuro-arthropathy (Charcot joints) in diabetes mellitus: a clinical study of 101 cases. *Medicine (Baltimore)* 1972;51:191–210.
- [25] Clouse ME, Gramm HF, Legg M, Flood T. Diabetic osteoarthropathy: clinical and roentgenographic observations in 90 cases. *Am J Roentgenol Radium Ther Nucl Med* 1974;121:22–33.
- [26] Mabileau G, Petrova NL, Edmonds ME, Sabokbar A. Increased osteoclastic activity in acute Charcot's osteoarthropathy: the role of receptor activator of nuclear factor- κ B ligand. *Diabetologia* 2008;51:1035–40.
- [27] Pitocco D, Zelano G, Giofrè G, Di Stasio E, Zaccardi F, Martini F, et al. *Diabetes Care* 2009;32:1694–7.
- [28] Frykberg RG, Mendezsoon E. Management of the diabetic Charcot foot. *Diabetes Metab Res Rev* 2000;16(Suppl. 1):S59–65.
- [29] Pinzur MS, Shields N, Trepman E, Dawson P, Evans A. Current practice patterns in the treatment of Charcot foot. *Foot Ankle Int* 2000;21:916–20.
- [30] McGill M, Molyneaux L, Bolton T, Ioannou K, Uren R, Yue DK. Response of Charcot's arthropathy to contact casting: assessment by quantitative techniques. *Diabetologia* 2000;43:481–4.
- [31] Armstrong DG, Todd WF, Lavery LA, Harkless LB, Bushman TR. The natural history of acute Charcot's arthropathy in a diabetic foot specialty clinic. *Diabet Med* 1997;14:357–63.
- [32] Sinacore DR. arthropathy inpatients with diabetes mellitus: healing times by foot location. *J Diabetes Complicat* 1998;12:287–93.
- [33] Lavery LA, Armstrong DG, Walker SC. Healing rates of diabetic foot ulcers associated with midfoot fracture due to Charcot's arthropathy. *Diabet Med* 1996;14:46–9.
- [34] Mehta JA, Brown C, Sargeant N. Charcot restraint orthotic walker. *Foot Ankle Int* 1998;19:619–23.
- [35] Guse ST, Alvin FG. Treatment of diabetic foot ulcers and Charcot neuroarthropathy using the patellar tendon-bearing brace. *Foot Ankle Int* 1997;18:675–7.
- [36] Yalsin S, Kocaoglu B, Berker N, Erol B. Conservative treatment of Charcot arthropathy in a series of spina bifida patients: the experience of one center and review of the literature. *J Pediatr Orthop B* 2007;16:376–9.
- [37] Boninger ML, Leonard Jr JA. Use of bivalved ankle-foot orthosis in neuropathic foot and ankle lesions. *J Rehabil Res Dev* 1996;33:16–22.
- [38] Hartsell HD, Fellner C, Saltzman CL. Pneumatic bracing and total contact casting have equivocal effects on plantar pressure relief. *Foot Ankle Int* 2001;22:502–6.
- [39] Jude EB, Selly PL, Burgess J, Lilleystone P, Mawer EB, Page SR, et al. Bisphosphonates in the treatment of Charcot neuroarthropathy: a double blind randomised controlled trial. *Diabetologia* 2001;44:2032–7.
- [40] Pitocco D, Ruotolo V, Caputo S, Mancini L, Collina CM, Manto A, et al. Six-month treatment with alendronate in acute Charcot neuroarthropathy: a randomized controlled trial. *Diabetes Care* 2005;28:1214–5.
- [41] Bem R, Jirkovska A, Fejfarova V, Skibova J, Jude EB. Intranasal calcitonin in the treatment of acute Charcot neuroosteoarthropathy: a randomized controlled trial. *Diabetes Care* 2006;29:1392–4.
- [42] Miller PD, Bolognese MA, Lewiecki EM, McClung MR, Ding B, Austin M, et al. Effect of denosumab on bone density and turnover in postmenopausal women with low bone mass after long-term continued, discontinued, and restarting of therapy: a randomized blinded phase 2 clinical trial. *Bone* 2008;43:222–9.
- [43] Cohen SB, Dore RK, Lane NE, Ory PA, Peterfy CG, Sharp JT, et al. Denosumab treatment effects on structural damage, bone mineral density, and bone turnover in Rheumatoid Arthritis: a twelve-month, multicenter, randomized, double-blind, placebo-controlled, phase II clinical trial. *Arthritis Rheum* 2008;58:1299–309.